Received: 4 July 2017 | Revised: 31 August 2017 | Accepted: 5 September 2017

DOI: 10.1111/cge.13135

WILEY CLINICAL GENETICS

ORIGINAL ARTICLE

mTOR mutations in Smith-Kingsmore syndrome: Four additional patients and a review

G. Gordo[1,2,3] | J. Tenorio[1,2] | P. Arias[1,2] | F. Santos-Simarro[1,4] | S. García-Miñaur[1,4] | J.C. Moreno[1,2] | J. Nevado[1,5] | E. Vallespin[1,5] | L. Rodriguez-Laguna[1,3] | R. de Mena[1,5] | I. Dapia[1,2] | M. Palomares-Bralo[1,5] | Á. del Pozo[1,6] | K. Ibañez[1,6] | J.C. Silla[1,6] | E. Barroso[1,2] | V.L. Ruiz-Pérez[1,7] | V. Martinez-Glez[1,3,4] | P. Lapunzina[1,2,4]

[1]Centro de Investigación Biomédica en Red de Enfermedades Raras (CIBERER), ISCIII, Madrid, Spain

[2]Molecular Endocrinology Section, Overgrowth Syndromes Laboratory, Instituto de Genética Médica y Molecular (INGEMM), IdiPAZ, Hospital Universitario la Paz, Universidad Autónoma de Madrid (UAM), Madrid, Spain

[3]Vascular Malformations Section, Instituto de Genética Médica y Molecular (INGEMM), IdiPAZ, Hospital Universitario la Paz, Universidad Autónoma de Madrid (UAM), Madrid, Spain

[4]Clinical Genetics Section, Instituto de Genética Médica y Molecular (INGEMM), IdiPAZ, Hospital Universitario la Paz, Universidad Autónoma de Madrid (UAM), Madrid, Spain

[5]Structural and Functional Genomics Section, Instituto de Genética Médica y Molecular (INGEMM), IdiPAZ, Hospital Universitario la Paz, Universidad Autónoma de Madrid (UAM), Madrid, Spain

[6]Bioinformatics Section, Instituto de Genética Médica y Molecular (INGEMM), IdiPAZ, Hospital Universitario la Paz, Universidad Autónoma de Madrid (UAM), Madrid, Spain

[7]IIB, Instituto de Investigación "Alberto Sols", Universidad Autónoma de Madrid (UAM), Madrid, Spain

Correspondence
Pablo Lapunzina, MD, PhD, Instituto de Genética Médica y Molecular (INGEMM), Instituto de Investigación Sanitaria del Hospital Universitario La Paz (IdiPAZ), Universidad Autónoma de Madrid, Centro de Investigación Biomédica en Red de Enfermedades Raras (CIBERER), ISCIII, Paseo de la Castellana 261-28046, Madrid, Spain.
Email: pablo.lapunzina@salud.madrid.org; plapunzina@ciberer.es
Víctor Martinez-Glez, MD, PhD, Instituto de Genética Médica y Molecular (INGEMM), Instituto de Investigación Sanitaria del Hospital Universitario La Paz (IdiPAZ), Universidad Autónoma de Madrid, Centro de Investigación Biomédica en Red de Enfermedades Raras (CIBERER), ISCIII, Paseo de la Castellana 261-28046, Madrid, Spain.
Email: vmartinezglez@salud.madrid.org

Smith-Kingsmore syndrome (SKS) OMIM #616638, also known as MINDS syndrome (ORPHA 457485), is a rare autosomal dominant disorder reported so far in 23 patients. SKS is characterized by intellectual disability, macrocephaly/hemi/megalencephaly, and seizures. It is also associated with a pattern of facial dysmorphology and other non-neurological features. Germline or mosaic mutations of the *mTOR* gene have been detected in all patients. The *mTOR* gene is a key regulator of cell growth, cell proliferation, protein synthesis and synaptic plasticity, and the mTOR pathway (PI3K-AKT-mTOR) is highly regulated and critical for cell survival and apoptosis. Mutations in different genes in this pathway result in known rare diseases implicated in hemi/megalencephaly with epilepsy, as the tuberous sclerosis complex caused by mutations in *TSC1* and *TSC2*, or the *PIK3CA*-related overgrowth spectrum (PROS). We here present 4 new cases of SKS, review all clinical and molecular aspects of this disorder, as well as some characteristics of the patients with only brain *mTOR* somatic mutations.

KEYWORDS

constitutive mosaicism, germline mosaicism, gonadal mosaicism, macrocephaly, megalencephaly, MINDS syndrome, *mTOR*, Smith-Kingsmore syndrome, somatic mosaicism

The first authors Gema Gordo and Jair Tenorio contributed equally to this study.

The senior authors Victor Martinez-Glez and Pablo Lapunzina contributed equally to this study.

Funding information
Instituto de Salud Carlos III, Grant/Award number: FEDER FUNDS FIS PI15/01481; "Todos Somos Raros" (Telemaraton TVE promoted by Fundación Isabel Gemio, Federación ASEM, and Federación Española de Enfermedades Raras), Grant/Award number: IP-17

1 | INTRODUCTION

Smith-Kingsmore syndrome (SKS) (MIM 616638), also known as MINDS (ORPHA 457485), is a rare syndrome, first described by Smith et al[1] and caused by mutations in the mammalian target of rapamycin (*mTOR*, MIM 601231) gene. The most consistent findings in SKS are intellectual disability (ID), developmental delay, megalencephaly and seizures (Table 1). There is moderate clinical variability, ranging from patients with macrocephaly, mild ID, and no convulsions, to severe forms in patients with intractable epilepsy, megalencephaly, severe ID, and autistic spectrum disorder (ASD). Other non-neurological features include facial dysmorphisms and small thorax.

SKS belongs to the group of "mTORopathies," a term introduced to describe neurological disorders characterized by altered cortical architecture, abnormal neuronal morphology and intractable epilepsy as a consequence of mTOR signalling hyperactivation, providing probably a histopathological substrate for epileptogenesis.[2,3] These mTORopathies-related epilepsies include: SKS, isolated hemimegalencephaly, ganglioglioma, focal cortical dysplasia (FCD), and tuberous sclerosis complex (TSC).[2,4]

Macrocephaly and hemi/megalencephaly—with or without normal cortex—is a rather prevalent clinical feature among different types of vascular and/or overgrowth syndromes caused by germline or post-zygotic mutations in different genes in the PI3K-AKT-mTOR pathway: megalencephaly-polymicrogyria-polydactyly-hydrocephalus syndrome (*AKT3* and *PIK3R2*),[5,6] megalencephaly-capillary malformation (MCAP; *PIK3CA*),[7] Bannayan-Riley-Ruvalcaba syndrome (*PTEN*),[8] Tenorio syndrome (*RNF125*),[9] isolated hemimegalencephaly (*PIK3CA* and *AKT3*),[10] and with syndromes with epilepsy, hemimegalencephaly and/or FCD due to mutations in *DEPDC5*, *NPRL2* and *NPRL3* genes, involved in mTORC1 regulation.[11] Axial skeletal overgrowth is not affected by mutations in *mTOR*, but megalencephaly is clearly a finding.[12] The main differences between the syndromes involved in this pathway are based on: (1) its germinal or somatic origin, causing generalized or segmental distribution patterns as in hemi or megalencephaly, (2) the degree of mosaicism, and (3) the presence of distinctive extra-cerebral manifestations, mostly the vascular malformations, nevi, and adipose overgrowth frequently found in the *PIK3CA*-related overgrowth spectrum (PROS).[10,13–15]

The *mTOR* gene is a key regulator of cell growth, cell proliferation, protein synthesis and synaptic plasticity. The mTOR pathway is highly regulated and critical for cell survival and apoptosis. It is known that *mTOR* negatively regulates autophagy in response to growth factors, nutritional status and stress responses. Thus, it would appear that impaired autophagy in neurons is directly related to unregulated expression of *mTOR* and that this plays some role in epilepsy.[12] mTORC1 inhibitors, including drugs currently approved for a variety of conditions, are clinically available inducers of autophagy.

The prevalence of SKS, with 23 patients reported so far, is still unknown. We here report on 4 new SKS patients with *mTOR* mutations and review all the clinical characteristics and molecular aspects of this disorder. We also discuss some characteristics of patients with brain somatic mutations in *mTOR* who show some similarities with individuals with SKS.

TABLE 1 Clinical findings in Smith-Kingsmore syndrome (SKS)

Very common (observed in more than 75% of patients)		
Intellectual disability	24/26	92.3%
Macrocephaly/megalencephaly	24/27	88.9%
Seizures	17/23	73.9%
Frequent (observed in 25%-75% of patients)		
CNS anomalies (other than hemimegalencephaly)	16/24	66.7%
Curly/wavy hair	8/13	61.5%
Ventriculomegaly	13/24	54.2%
Macrosomia at birth/large for gestational age	12/27	44.4%
Speech anomaly	9/27	33.3%
Dysmorphic facial features	9/27	33.3%
Autistic spectrum disorder	8/27	29.6%
Rare (observed in less than 25% of patients)		
Hypotonia	5/27	18.5%
Diastasis recti/herniae	4/27	14.8%
Capillary malformation of the skin	4/27	14.8%
Hypomelanosis/patchy hypopigmentation of skin	4/27	14.8%
Strabismus	4/27	14.8%
Abnormal corpus callosum	4/27	14.8%
Small thorax	4/27	14.8%
Hyperactivity	3/27	11.1%
Café-au-lait spots	3/27	11.1%
Pes planus/talipes	3/27	11.1%
Abnormal gait	3/27	11.1%
Polymicrogyria	2/27	7.4%
Prominent abdomen	2/27	7.4%
Hemangiomas	2/27	7.4%
Iris colobomata	2/27	7.4%
Criptorchydism	2/27	7.4%
Asthma	2/27	7.4%
Lactose intolerance	2/27	7.4%
Hypospadias	1/27	3.7%
Neonatal hypoglycaemia	1/27	3.7%
IgA deficiency	1/27	3.7%
Persistent food allergies	1/27	3.7%
Intestinal polyps	1/27	3.7%

2 | PATIENTS, MATERIALS AND METHODS

2.1 | Patients

All studies in this project were approved by the Ethics Committee of the Hospital Universitario La Paz (reference PI-1919), with informed consent. We retrospectively reviewed the patients enrolled in the Spanish Overgrowth Registry (RESSC),[16] selecting those with macrocephaly. Four patients from 3 families were finally enrolled. Patient 1 had macrocephaly and ID, and the other 3 patients were referred with clinical diagnosis of macrocephaly-capillary malformation.

To update the phenotype in SKS, we performed a retrospective review of the clinical characteristics including the 4 patients described herein, and the 23 patients previously reported to date (Table 2). These patients were ascertained from a series of patients with focal epilepsy, ID, brain anomalies and megalencephaly or hemimegalencephaly.[1,12,17–22] Reported patients with only brain somatic mutations of *mTOR* were also reviewed.[10,17,23–25]

2.2 | NGS studies

Genomic DNA was extracted from peripheral blood lymphocytes from all patients. DNA was also extracted from saliva, hyperpigmented skin and hypopigmented skin samples from Patient 2.

A deep Next Generation Sequencing (NGS) panel, with an average expected reading depth of ×500, was designed to study 20 genes known to cause developmental syndromes characterized by overgrowth and/or vascular anomalies in the form of somatic mosaicism: *mTOR*, *NRAS*, *AKT3*, *PIK3CA*, *FGFR3*, *RASA1*, *TSC1*, *GNAQ*, *PTEN*, *HRAS*, *PTPN11*, *KRAS*, *CCND2*, *AKT1*, *DICER1*, *TSC2*, *NF1*, *MAP3K3*, *PIK3R2*, and *AKT2*. NGS custom panel was designed with NimbleDesign software (Roche NimbleGen, Inc., Pleasanton, CA): hg19 NCBI Build 37.1/GRCh37, targeting >98% of all exons (RefSeq) for these genes. For each sample, paired-end libraries were created according to the standard NGS protocols KAPA HTP Library Preparation Kit for Illumina platforms, SeqCap EZ Library SR and NEXTflex-96 Pre Capture Combo Kit for indexing. The captured DNA samples were sequenced on a NextSeq 500 instrument (Illumina, Inc., San Diego, CA) according to the standard operating protocol.

The analysis of the sequenced reads was performed with 2 different in-house bioinformatic pipelines: germline and mosaic. In the germline pipeline, the reads were filtered and low-quality nucleotides were removed. Bowtie2[26] was used for mapping and local realignment/recalibration was performed around indels to improve possible mapping-related misalignment. The variant discovery was carried out by a combination of GATK Haplotype Caller[27] and LACONv (in preparation) tools.

In the mosaic pipeline, variants were analyzed with independent tools under very low constraints of quality and depth. Variants were identified with samtools mpileup[28] followed by variant calling using bcftools v1.3.[29] The quality per alignment and nucleotide were set to 0.7. Then, this first raw vcf file was annotated with their alternative variant allele fraction (AVAF) and the maximum of alternative variant allele fraction (MAVAF) in those sites with more than 1 alternative allele identified. The variants with AVAF below the threshold were filtered. In addition, the vcf file was reformatted by splitting the multiallelic sites into these primitives and the variant positions were normalized. Finally, the vcf were enriched with information of the overlapping of each variant in a sample with the remaining samples of the run.

2.3 | Sanger sequencing and pyrosequencing

Non-mosaic heterozygous variants and variants present in more than 15% of the reads in the deep-sequencing data were validated by Sanger sequencing in DNA blood samples from patients, parents, and in sperm sample from the father of Patients 3 and 4 (siblings). Primers were previously designed using *Primer3* (http://bioinfo.ut.ee/primer3-0.4.0/) and *SNPs Check3* (https://secure.ngrl.org.uk/SNPCheck/) tools. Sequencing was performed using polymerase chain reaction standard methods and a 96-capillary ABI 3730xl ADN analyser (Applied Biosystem, Foster, California). Mosaic variants between the 5% and 15% read fraction range were confirmed by pyrosequencing. Primers were designed with the PyroMark software, and pyrosequencing was performed with the PyroMark Q96 MD instrument (Qiagen, Hilden, Germany), according to manufacturer's protocol.

3 | RESULTS

3.1 | Clinical features in SKS

Clinical features in our 4 new patients with SKS and the review of the 23 patients previously described in the literature up to date, including clinical, radiological and genomic findings, are summarized in Table 2. Facial features in our patients are shown in Figure 1.

Macrocephaly and hemi/megalencephaly—mostly with central nervous system (CNS) magnetic resonance imaging (MRI) findings—were found in 88.9% of individuals with SKS. Mean values of macrocephaly in all reported patients is +3.83 (±0.98) SD, in the moderate to severe range. Hydrocephalus, ASD, seizures (see below) and attention deficit hyperactivity disorder (any of them) are usually present (Table 1). Generalized hypotonia may be present in small children with SKS. In some cases, only non-specific MRI abnormalities, including thin corpus callosum and/or ventricular dilatation, can be found. FCD seems to be more frequent in patients with brain mosaic mutations in *mTOR* than in patients with SKS.

Convulsions and associated symptoms are constant findings (73.9%). Electroencephalogram (EEG) anomalies includes: right occipitoparietal spikes and slow activity, theta activity intermixed with normal background activity, polyspike waves and slow waves activity, slow and sharp waves during sleep (both diffuse and focal), persistent diffuse sharp and slow wave activity, mild slow background, diffuse and centro-temporal epileptiform discharges, irregular slowing of background rhythms and frequent bursts of generalized slow wave convulsions.

ID is common in SKS, and may be severe, moderate or mild. It could appear alone or in combination with delay or absent speech, as well as distorted articulation.

TABLE 2 Clinical, radiological and genomic findings in 27 Smith-Kingsmore syndrome (SKS) patients with germline or constitutive mosaic mutations in *mTOR*

	Smith et al[1]	Epi4k Consortium et al[22]	Baynam et al[21]	Baynam et al[21]	Baynam et al[21]	Mroske et al[19]	Mroske et al[19]
Year	2013	2013	2015	2015	2015	2015	2015
Origin			Australian aborigen	Australian aborigen	Australian aborigen		
Intellectual disability (ID)			Patient 1	Patient 2	Patient 3	Proband	Brother
Age (y)	1.5	1.5	7	3	2	5	23
Gender	F	M	F	M	M	M	M
Weight/height postnatal	N		N	N		N	N
Megalencephaly/ macrocephaly	+	+	+	+	+	+	+
OFC	>+3 SD		>+3 SD	>+3 SD	>+3 SD	+5 SD	+5 SD
Large for gestational age	–		–	+	+	+	+
Autism						+	+
Hyperactivity			+				
Intellectual disability	+	+	Severe	Severe	Severe	Moderate	+
Speech						Delay	Delay
Seizures	Intractable	+	+	+	+	–	–
Diastasis recti or umbilical herniae	+		+	+	+		
Other	Face: NSLF, large anterior fontanelle, frontal bossing, midface hypoplasia, small chin. Hypertelorism, downslanting palpebral fissures, depressed nasal bridge. Full and widely spaced brows. Thick eyelashes. Other: hypotonia. Hypoglycemia and thrombocytopenia, sacral cleft, umbilical hernia, hands had a trident appearance with short proximal phalanges.	Seizures: infantile spam and myoclonic epilepsy.	Face NSLF8. Abdominal region: prominent. Hepatomegaly at 20 wk gestation. Renal asymmetry. Skin: CLS. Other: Rocker-bottom heels, pes planus, broad feet, an ossifying anterior fontanel, large ear lobes. Aortic sinus to right atrial fistula.	Face NSLF8. Chest: small in infancy. Abdominal region: prominent. Skin: CLS. Deep palmar and plantar creases. Other: IGa deficiency.	Face NSLF8. Chest: small in infancy. Abdominal region: prominent. Skin: CLS. Deep palmar and plantar creases.	Eyes: 3, genitalia: 5, other: 6	Eyes: 4, genitalia: 5, Other: 7
CNS image	Callosal dysgenesis and mild dilatation of the posterior horns of the lateral ventricles.		Mild prominence of the ventricular system, hypogenesis of the body and the splenium of the corpus callosum, generalized white	Megalencephaly, perisylvian polymicrogyria, mild prominence of the lateral ventricles, moderate hypogenesis		Megalencephaly	Mild ventricular prominence, hypoplastic CC, small medulla

TABLE 2 (Continued)

	Smith et al[1]	Epi4k Consortium et al[22]	Baynam et al[21]	Baynam et al[21]	Baynam et al[21]	Mroske et al[19]	Mroske et al[19]
			matter loss, particularly in the peritrigonal regions. Small mesencephalon, pons and medulla.	of the corpus callosum, heterotopic grey matter in the right frontal lobe, small left middle cranial fossa.			
Genomic change	c.4448G>T	c.4785G>A	c.5395G>A	c.5395G>A	c.5395G>A	c.5395G>A	c.5395G>A
Protein change	p.Cys1483Phe	p.Met1595Ile	p.Glu1799Lys	p.Glu1799Lys	p.Glu1799Lys	p.Glu1799Lys	p.Glu1799Lys
Type of mutation	Probably GOF		GOF	GOF	GOF	GOF	GOF
Type of inheritance	de novo	de novo	Maternal gonadal mosaicism	Maternal gonadal mosaicism	Maternal gonadal mosaicism	Gonadal mosaiscism	Gonadal mosaiscism
	Mirzaa et al[18]	**Mirzaa et al[18]**	**Mirzaa et al[18]**	**Mirzaa et al[18]**	**Ghahramani et al[20]**	**Ghahramani et al[20]**	**Moller et al[17]**
Year	2016	2016	2016	2016	2015	2015	2016
Origin							Danish
ID	LR12-379a1	LR12-379a2	LR14-012	LR15-065	Case 1	Case 2	Patient 7
Age (y)	17	17	3				8
Gender	M	M	F	M			F
Weight/height postnatal	N	N	N	N			
Megalencephaly/ macrocephaly	+	+	+	+	+	+	+
OFC							+3.31 SD
Large for gestational age					+	+	
Autism	+	+	+		+	+	
Hyperactivity							
Intellectual disability	+	+	+	Mild	+	+	
Speech	Absent	Absent					
Seizures	+	+			+	+	+
Diastasis recti or umbilical herniae					–	–	
Other			Skin: 1	Abdominal region: 2	Face: dysmorphic facial features. Skin: hypomelanosis of Ito.	Face: dysmorphic facial features. Skin: hypomelanosis of Ito.	
CNS image	Megalencephaly	Megalencephaly	Mild dysmyelination mild ventriculomegaly	Subtle undersulcation, mild dysmyelination, moderate ventriculomegaly	Hemimegalencephaly	Hemimegalencephaly	
Genomic change	c.5395G>A	c.5395G>A	c.5395G>A	c.5395G>A	c.5395G>A	c.4448G>A	c.5494G>A
Protein change	p.Glu1799Lys	p.Glu1799Lys	p.Glu1799Lys	p.Glu1799Lys	p.Glu1799Lys	p.Cys1483Tyr	p.Ala1832Thr

TABLE 2 (Continued)

	Mirzaa et al[18]	Mirzaa et al[18]	Mirzaa et al[18]	Mirzaa et al[18]	Ghahramani et al[20]	Ghahramani et al[20]	Moller et al[17]
Type of mutation	GOF	GOF	GOF	GOF	GOF	Probably GOF	
Type of inheritance					Germline de novo	Germline de novo	Germline de novo
	Moller et al[17]	**Moller et al[17]**	**Moller et al[17]**	**Moller et al[17]**	**Moller et al[17]**	**Moller et al[17]**	**Moller et al[17]**
Year	2016	2016	2016	2016	2016	2016	2016
Origin	Danish	Danish	Italian	USA	USA	USA	USA
ID	Patient 8a	Patient 8b	Patient 9	Patient 10a	Patient 10b	Patient 11	Patient 12
Age (y)	44	70	6	23	23	8	2.5
Gender	F	F	M	F	F	M	F
Weight/height postnatal							
Megalencephaly/ macrocephaly	–	–	+	+	+	–	+
OFC	−0.11 SD	+1.52 SD	+2.8 SD	+5.8 SD	+4.9 SD	+0.95 SD	+4.1 SD
Large for gestational age							
Autism							
Hyperactivity							Behavioural outbursts
Intellectual disability	–	–	Mild	+	+	+	Moderate
Speech				Delay	Delay		
Seizures	+	+	+	+	+	+	–
Diastasis recti or umbilical herniae							
Other	No dysmorphic features	No dysmorphic features	No dysmorphic features	Facial dysmorphy: prominent forehead, low-set ears, gingival hyperplasia, frontal bossing, kyphosis, micrognathia, long thin extremities. Other: hypotonia, shuffling gait.	Facial dysmorphy: prominent forehead, low-set ears, gingival hyperplasia, frontal bossing, kyphosis, micrognathia, long thin extremities. Other: hypotonia, shuffling gait.	Dysmorphology not carried out. Other: Ataxic gait.	Facial dysmorphy: frontal bossing, broad depressed nasal root, coarse facial features
CNS image	Incomplete inversion of left hippocampus, pineal gland cyst, arachnoidal cyst at 42 y (1.5 T)	Normal	Thin corpus callosum, ventricular dilatation at 2 y 8 mo and 5 y (3 T)	Ventricular prominence with mild extra ventricular enlargement at 6 mo (1.5 T)	Mild ventricular prominence at 6 mo (1.5 T)	Normal at 18 mo	Mild ventricular dilatation and increased extra-axial spaces at 20 mo (1.5 T)
Genomic change	c.7501A>G	c.7501A>G	c.4468T>C	c.5663T>G	c.5663T>G	c.4785G>A	c.6981G>A
Protein change	p.Ile2501Val	p.Ile2501Val	p.Trp1490Arg	p.Phe1888Cys	p.Phe1888Cys	p.Met1595Ile	p.Met2327Ile
Type of mutation							

TABLE 2 (Continued)

	Moller et al[17]	Moller et al[17]	Moller et al[17]	Moller et al[17]	Moller et al[17]	Moller et al[17]	Moller et al[17]
Type of inheritance	Germline maternal	Transmitted to daughter	Germline de novo	Germline de novo (twin pair)	Germline de novo (twin pair)	Germline de novo	Germline de novo
	Moosa et al[12]	**Moosa et al[12]**	**P1**	**P2**	**P3**	**P4**	
Year	2017	2017	2016	2016	2016	2016	
Origin	Germany	Germany	Spain	Spain	Spain	Spain	
ID	Index	Younger brother	OGS771	OGS1464	OGS1092	OGS1093	
Age (years)	7	2.5	16	8	9	10.5	
Gender	F	M	M	M	F	M	
Weight/height postnatal			Tall	N	N	N	
Megalencephaly/macrocephaly	+	+	+	+	Progressive	Progressive	
OFC	+4.9 SD	+4 SD	>+4 SD	+4 SD	>+3 SD	>+6.5 SD	
Large for gestational age	+	+	+	+	+	+	
Autism			+		–	–	
Hyperactivity			+		–	–	
Intellectual disability	+	+	Mild-moderate	+	Severe	Severe	
Speech			Delay		Delay	Delay	
Seizures			–	+	–	–	
Diastasis recti or umbilical herniae			–	–	–	–	
Other	Abdominal region: multiple polyps in the ileum, cecum, and colon. Bilateral cystic kidneys (inherited from his father).		Face: deep set eyes. Triangular, small chin. Other: large hands, camptodactyly.	Face: hypertelorism, open mouth appearance and smooth philtrum. Skin: hyperpigmentation following Blaschko lines in arms and legs. Other: Strabismus. Hypotonia, neonatal hypoglycaemia. Hypospadias.	Face: facial capillary malformation, smooth philtrum. Skin: capillary malformation in shoulders, and areas of hypopigmentation and hyperpigmentation. Other: Strabismus. Delayed bone age, hypotonia.	Face: smooth philtrum, posteriorly rotated ears. Skin: reticular capillary malformation, peri-axillary capillary malformation. Other: Bilateral talipes equinovarus, hypotonia, decreased subcutaneous fat, delayed bone age.	
CNS image	Mildly dilated ventricles		Megalencephaly	Ventriculomegaly, gliosis, cavum vergae, periventricular venous malformation	N	Ventriculomegaly, hydrocephaly	
Genomic change	c.5395G>A	c.5395G>A	c.5395G>A	c.4448G>A	c.6605T>G	c.6605T>G	
Protein change	p.Glu1799Lys	p.Glu1799Lys	p.Glu1799Lys	p.Cys1483Tyr	p.Phe2202Cys	p.Phe2202Cys	
Type of mutation	GOF	GOF	GOF	GOF	Probably GOF	Probably GOF	
Type of inheritance	Gonadal mosaicism	Gonadal mosaicism	Germline de novo	Mosaic in all studied tissues (blood, saliva, skin)	Gonadal mosaicism (probably maternal)	Gonadal mosaicism (probably maternal)	

Abbreviations: GOF, gain-of-function. OFC, occipitofrontal circumference. NSLF, Noonan syndrome-like face. CLS, Cafe-au-lait lesion(s). CNS, central nervous system. CC, corpus callosum.

FIGURE 1 Facial features of patients with Smith-Kingsmore syndrome. Patients 1, 2, 3 and 4 show mixed characteristics of the 2 different phenotypes or gestalts described so far: macrocephaly (P1, P2, P3, P4), large forehead (P2, P3, P4), bitemporal narrowing (P1, P3, P4), hypertelorism (P2, P3, P4), downslanting palpebral fissures (P4), an open mouth appearance (P1, P2, P4), long philtrum (P3, P4), and triangular face with pointed chin (P1, P3, P4). Uncommon clinical features included facial capillary malformation (slightly appreciable in P3), deep set eyes (P1), strabismus (P3), smooth philtrum (P2, P3, P4) and posteriorly rotated ears (P4)

Some patients exhibit, when reported, a pattern of facial dysmorphology. At least 2 different phenotypes or *gestalts* have been described. One group of patients present a Noonan syndrome-like aspect, including curly hair, frontal bossing, tall forehead, downslanting palpebral fissures, bitemporal narrowing, an open mouth appearance, a prominent and long philtrum, flat nasal bridge, macrostomia, an open mouth posture, hypertelorism, and a short nose with a depressed nasal bridge. Other individuals show only large forehead, macrocephaly and triangular face, with pointed chin, or a face without a constant pattern or typical gestalt (Figure 1). The neck may be short or normal. Only a few patients have a webbed neck.

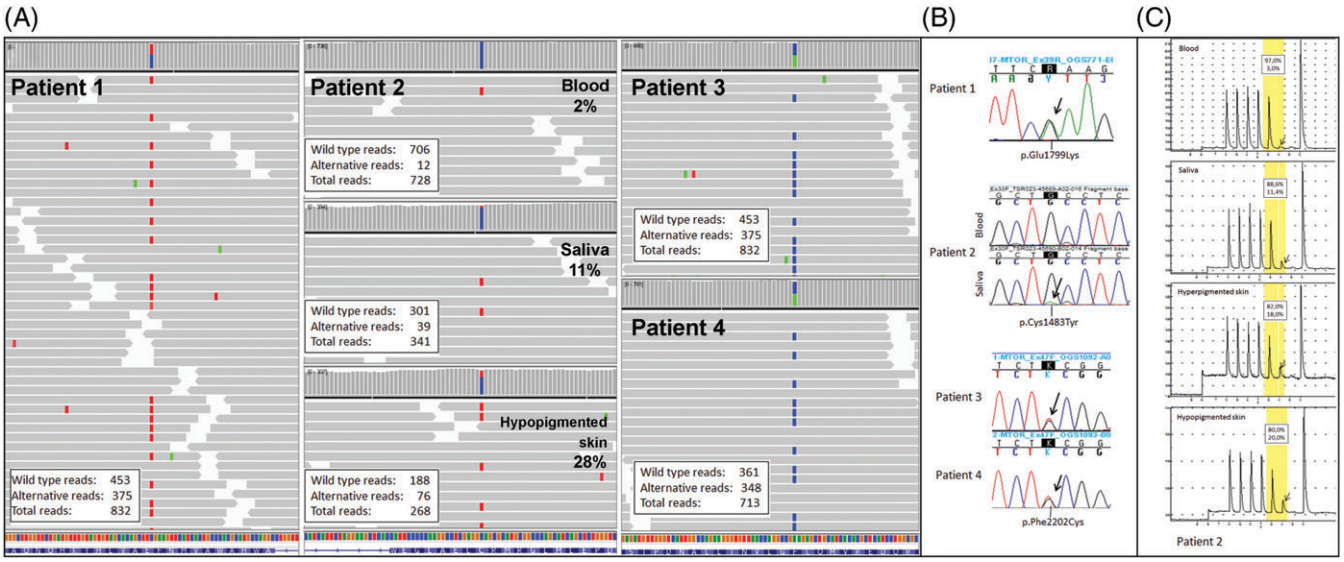

FIGURE 2 Next-generation sequencing results and variants validation by Sanger sequencing or pyrosequencing. (A) de novo *mTOR* heterozygous variant c.5395G>A (p.Glu1799Lys) in Patient 1, constitutive mosaic variant c.4448G>A (p.Cys1483Tyr) in Patient 2 with different mosaicism levels in blood, saliva and hypopigmented skin, and the heterozygous variant c.6605T>G (p.Phe2202Cys) in Patients 3 and 4. (B) Sanger sequencing showing variants from Patients 1 to 4. For Patient 2, Sanger from saliva sample shows a very low peak of A (panel B: Patient 2, black arrow) representing the low mosaicism. (C) Pyrosequencing results from different sample types in Patient 2. Black arrows show different mosaicism levels in each tissue (blood 3%, saliva 11.4%, hyperpigmented skin 18% and hypopigmented skin 20%)

TABLE 3 Reported patients with focal cortical dysplasia (FCD) and somatic mutations in *mTOR*

	Lee et al[10]	Leventer et al[25]	D'Gama et al[33]	Lim and Lee[23]	Lim and Lee[23]	Lim and Lee[23]	Lim and Lee[23]	Lim and Lee[23]	Lim and Lee[23]	Lim and Lee[23]	Lim and Lee[23]	Lim and Lee[23]	Lim and Lee[23]	Lim and Lee[23]
Year	2012	2015	2015	2016	2016	2016	2016	2016	2016	2016	2016	2016	2016	2016
Origin	USA	Australia	USA	Korea	Korea	Korea	Korea	Korea	Korea	Korea	Korea	Korea	Korea	Korea
Gender	M	M	M	F	F	F	M	M	F	F	M	M	F	F
ID	HME-1563	L1	HME-08	FCD4	FCD6	FCD91	FCD104	FCD105	FCD107	FCD113	FCD116	FCD121	FCD128	FCD143
Age at surgery	5 y	10 mo		5 y 2 mo	5 y	7 y 1 mo	1 y 2 mo	3 y 7 mo	7 y 3 mo	10 y	7 y 9 mo	11 mo	4 y 4 mo	2 y 10 mo
Hemimegalencephaly	+	+	+											
Brain pathology	CD, CN, EN	CD, DN, Subtle AGWM, ACS	NA	CD, DN	CD, DN	CD, DN, VDLCH, AGWM	CD, DN	CD, DN	CD, DN, BC	CD, DN, BC	CD, DN, BC	CD, DN, BC	CD, DN, BC	CD, DN, BC
FCD type		FCD IIa	DCD	FCD IIa	FCD IIa	FCD IIa	FCD IIa	FCD IIa	FCD IIb	FCD IIb	FCD IIb	FCD IIb	FCD IIb	FCD IIb
Seizures type	Sz free	IED, FSD	CPS											
Skin	Hypomelanosis of Ito	NA	NA	NA	NA	NA	NA	NA	NA	NA	NA	NA	NA	NA
Tissue	Brain	Brain	Brain	Brain	Brain	Brain	Brain	Brain	Brain	Brain	Brain	Brain	Brain	Brain
Percentage of mutation burden	8-36	8.3	44	4.11-9.63	4.57-6.90	2.99	1.80	1.63	2.41	3.05	3.25	2.64	6.38	2.82
Genomic change	c.4448C>T	c.4487T>G	c.5005G>T	c.7280T>C	c.7280T>C	C.6577C>T	c.1871G>A	c.5126G>A	c.6644C>T	c.7280TzA	c.5930C>A	c.4348T>G	c.4447T>C	c.6644C>T
Protein change	p.Cys1483Tyr	p.Trp1456Gly	p.Ala1669Ser	p.Leu2427Pro	p.Leu2427Pro	p.Arg2193Cys	p.Arg624His	p.Arg1709His	p.Ser2215Phe	p.Leu2427Gln	p.Thr1977Lys	p.Tyr1450Asp	p.Cys1483Arg	p.Ser2215Phe
Type of mutation	GOF	GOF	GOF	GOF	GOF	GOF	GOF	GOF	GOF	GOF	GOF	GOF	GOF	GOF
Type of inheritance	Somatic	Somatic	Somatic	Somatic	Somatic	Somatic	Somatic	Somatic	Somatic	Somatic	Somatic	Somatic	Somatic	Somatic

	Lim and Lee[23]	Nakashima et al[24]	Nakashima et al[24]	Nakashima et al[24]	Nakashima et al[24]	Nakashima et al[24]	Nakashima et al[24]	Moller et al[17]	Moller et al[17]	Moller et al[17]	Moller et al[17]	Moller et al[17]	Moller et al[17]
Year	2016	2016	2016	2016	2016	2016	2016	2016	2016	2016	2016	2016	2016
Origin	Korea	Japan	Japan	Japan	Japan	Japan	Japan	French	French	French	French	French	French
Gender	F	M	F	M	F	M	M	F	M	M	M	M	M
ID	FCD145	11 683	15 622	16 578	14 434	16 964	17 424	P1	P2	P3	P4	P5	P6
Age at surgery	4 y 1 mo	9 and 10 y (twice)	23 y	7 and 10 y (twice)	4 and 10 y (twice)	6 y	5 y						
Hemimegalencephaly													
Brain pathology	CD, DN, BC	DN, BC	DN, BC	DN, BC	DN, BC	DN, BC	DN, BC	CD, DN, BC	CD, DN, BC	CD, DN	CD, DN, BC	CD, DN	CD, DN, BC
FCD type	FCD IIb	FCD IIb	FCD IIb	FCD IIb	FCD IIb	FCD IIb	FCD IIb	FCD IIb	FCD IIb	FCD IIa with BCL	FCD IIb	FCD IIa	FCD IIb
Seizures type		CPS	CPS	CPS	Spasms, CPS	CPS, Spasms	sGTCS, hemiclonic sz	LHD, ASz, TSz	ED, RHD	CSz	Spasms, CEM	Spasms, CEM	NSz, LOC, GE
Skin	NA	NA	NA	NA	NA	NA	NA	NA	NA	NA	NA	NA	NA
Tissue	Brain	Brain	Brain	Brain	Brain	Brain	Brain	Brain	Brain	Brain	Brain	Brain	Brain
Percentage of mutation burden	1.46	1.54	1.65	1.59	3.11	4.87	9.31	6.31-6.8	3.15-2.62	1.13-0.93	3.62-3.67	1.6-1.06	2.46; 2.41
Genomic change	c.5930C>A	c.6644C>A	c.4376C>A	c.4379T>C	c.6644C>T	c.4379T>C	c.6644C>A	c.6644C>T	c.6644C>T	c.6644C>T	c.6644C>A	c.6644C>A	c.4379T>C; c.4375G>T
Protein change	p.Thr1977Lys	p.Ser2215Tyr	p.Ala1459Asp	p.Leu1460Pro	p.Ser2215Phe	p.Leu1460Pro	p.Ser2215Tyr	p.Ser2215Phe	p.Ser2215Phe	p.Ser2215Phe	p.Ser2215Tyr	p.Ser2215Tyr	p.Leu1460Pro; p. Ala1459Ser

TABLE 3 (Continued)

	Lim and Lee[23]	Nakashima et al[24]	Nakashima et al[24]	Nakashima et al[24]	Nakashima et al[24]	Nakashima et al[24]	Nakashima et al[24]	Moller et al[17]	Moller et al[17]	Moller et al[17]	Moller et al[17]	Moller et al[17]	Moller et al[17]
Type of mutation	GOF	GOF	GOF	GOF	GOF	GOF	GOF	GOF	GOF	GOF	GOF	GOF	GOF
Type of inheritance	Somatic	Somatic	Somatic	Somatic	Somatic	Somatic	Somatic	Somatic	Somatic	Somatic	Somatic	Somatic	Somatic

Abbreviations: ACS, abnormal cerebral sulcation; AGWM, abnormality of the gray-white matter; ASz, atonic seizures; BC, balloon cells; BCL, balloon cells-like; CD, cortycal dyslamination; CEM, clonic eye movements; CN, cytomegalic neuron; CPS, complex partial seizure; Csz, clonic seizures; DCD, diffuse cortical dysplasia; DN, dysmorphic neurons; ED, eye deviation; EN, ectopic neurons; F, female; FCD, focal cortical dysplasia; FDS, focal dyscognitive seizures; GE, gestural automatism; GOF, gain-of-function; IED, interictal epileptiform discharges; LFPF, left fronto-parietal focus; LHD, left head deviation; LOC, loss of consciousness; M, male; NA, not applicable; NSz, nocturnal seizures; RHD, right hand dystonia; sGTCS, secondarily generalized tonic-clonic seizure; sz, seizure; TSz, tonic seizures; VDLCH, volume decreased of the left cerebral hemisphere.

Some patients had capillary malformations—similar to those observed in MCAP—hemangiomata, hepatic vascular malformations, and a small thorax with protruding abdomen. Unlike some overgrowth syndromes, visceromegaly is not common. Cryptorchidism has been observed only in 2 siblings, and one patient also had hypospadias. Multiple intestinal polyps described by Moosa et al in a 7-year-old brother[12] should be taken into account in SKS as reported patients may not have been evaluated for this or may not be old enough to have developed polyps yet.

3.2 | Molecular results

There is no clear genotype-phenotype correlation in either the 27 patients with SKS or in the 27 cases described with somatic brain alteration. The variants described are located along all exons of *mTOR*. However, there are some hotspots: the c.5395G>A;p.Glu1799Lys gain-of-function (GOF) variant affecting the FRAP–ATM–TTRAP (FAT) domain of the protein has been detected in 48.1% (13/27) of SKS patients (Figure 2, Table 2), and in cases with brain somatic *mTOR* variants the most frequently affected amino acid is the serine at position 2215 (p.Ser2215Phe and p.Ser2215Tyr), found in 37% (10/27) of the patients (Table 3). The remaining patients with SKS or somatic alterations had different less or not recurrent mutations, mostly affecting the FAT (22/31, 71.0%) and kinase (6/31, 19.4%) domains of the protein (Figure 3). No mutations have been described in the FKBP12-rapamycin-binding (FRB) or C-terminal FAT (FATC) domains, neither in SKS nor in somatic cases. The penetrance in SKS seems to be 100% as all patients with a germline or mosaic *mTOR* mutation have had clinical findings; however, this may change in the future due to current ascertainment bias.

Germline *mTOR* mutations have been found in 92.6% (25/27) of the patients with SKS. One of the patients reported by Ghahramani, as well as Patient 2 (P2) described in this study, had constitutive, mosaic *mTOR* mutations, because the mutated allele was detected in low percentages in all tissues studied, including blood. Case 2 from Ghahramani showed increased abundance of the mutant allele in the affected skin (36%) vs blood (1%).[20] In our study, Patient 2 showed by NGS the mutant allele in 2% (12/720) of the reads in blood sample, 11% (39/341) in saliva, 18% (only by pyrosequencing) in hyperpigmented skin, and 28% (76/268) in hypopigmented skin, all confirmed by pyrosequencing (Figure 2).

In 9 out of 27 SKS patients (33.3%) gonadal mosaicism has been suspected. In the case of the family studied by Baynam et al, the mutation p.Glu1799Lys was transmitted in the mother's germline, as all 3 children had different fathers.[21] In the family reported by Mroske et al, the mutation p.Glu1799Lys found in 2 siblings (of 6 and 23 years) was not detected in blood sample of either parent.[19] In the family reported by Moosa et al, high-depth sequencing of parental blood samples did not detect the presence of mosaicism for the mutation p.Glu1799Lys, which could be localized in the chromosome of paternal origin.[12] In the family described herein the mutation p.Phe2202Cys was detected in blood samples from the 2 siblings, and was not present in blood samples from either parent or sperm sample from the father, thus maternal gonadal mosaicism is suspected.

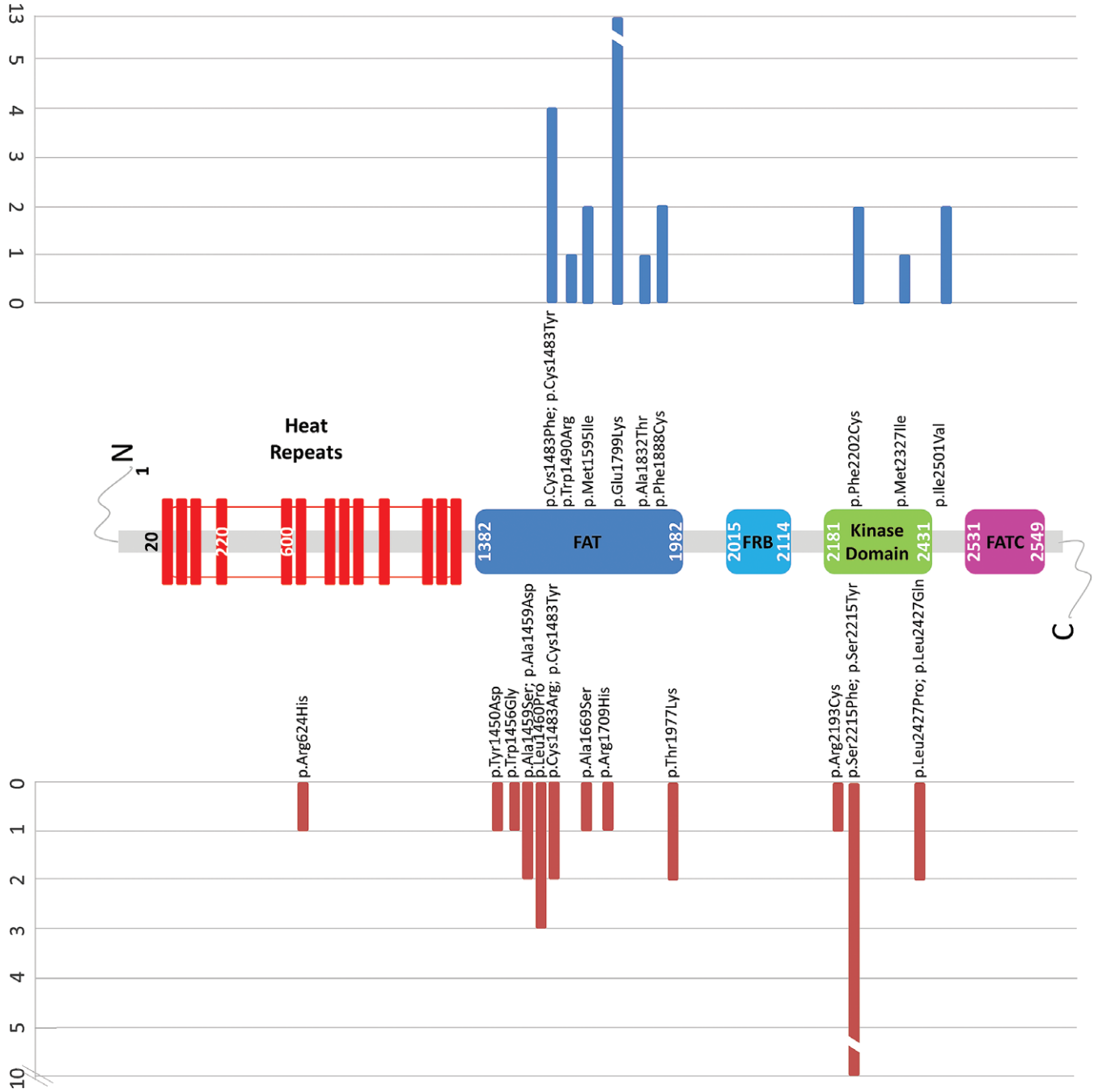

FIGURE 3 Germline mutations described in *mTOR* in patients with Smith-Kingsmore syndrome (upper panel, blue bars) and somatic mutations in patients with only brain involvement (lower panel, red bars). Data represent the localization and the frequency for each *mTOR* mutation. N: N terminus; C: C terminus. Note that the vast majority of germline mutations (blue bars) clustered in the FAT and kinase domains

4 | DISCUSSION

SKS is a rare, recently described disorder of the mTOR pathway. We report 4 new patients, review the literature for previously published cases of SKS, and compare them with reported cases of brain somatic *mTOR* variants.

SKS belongs to the group of "mTORopathies," which also includes patients with *mTOR* somatic mutations—as tissue mosaicism—including neoplastic tissues (Table 3), and patients with mutations in other mTOR regulatory genes (eg, *TSC1*, *TSC2*, *AKT3*, *DEPDC5*) (Figure 4). We have decided to maintain the eponym SKS only for patients with *mTOR* mutations present in all tissues, either germinal or as a constitutive mutation present in mosaic form, therefore present in all cell types but not in 100% of the cells, to which hereafter we will call "constitutive mosaicism."

Analysing the 4 patients described here and the 23 cases of SKS previously reported in the literature, we have seen that the major diagnostic features of SKS are ID (92.3%), macrocephaly/megalencephaly or hemimegalencephaly (88.9%) and seizures (73.9%). Non-neurological symptoms are also common, and a facial gestalt is

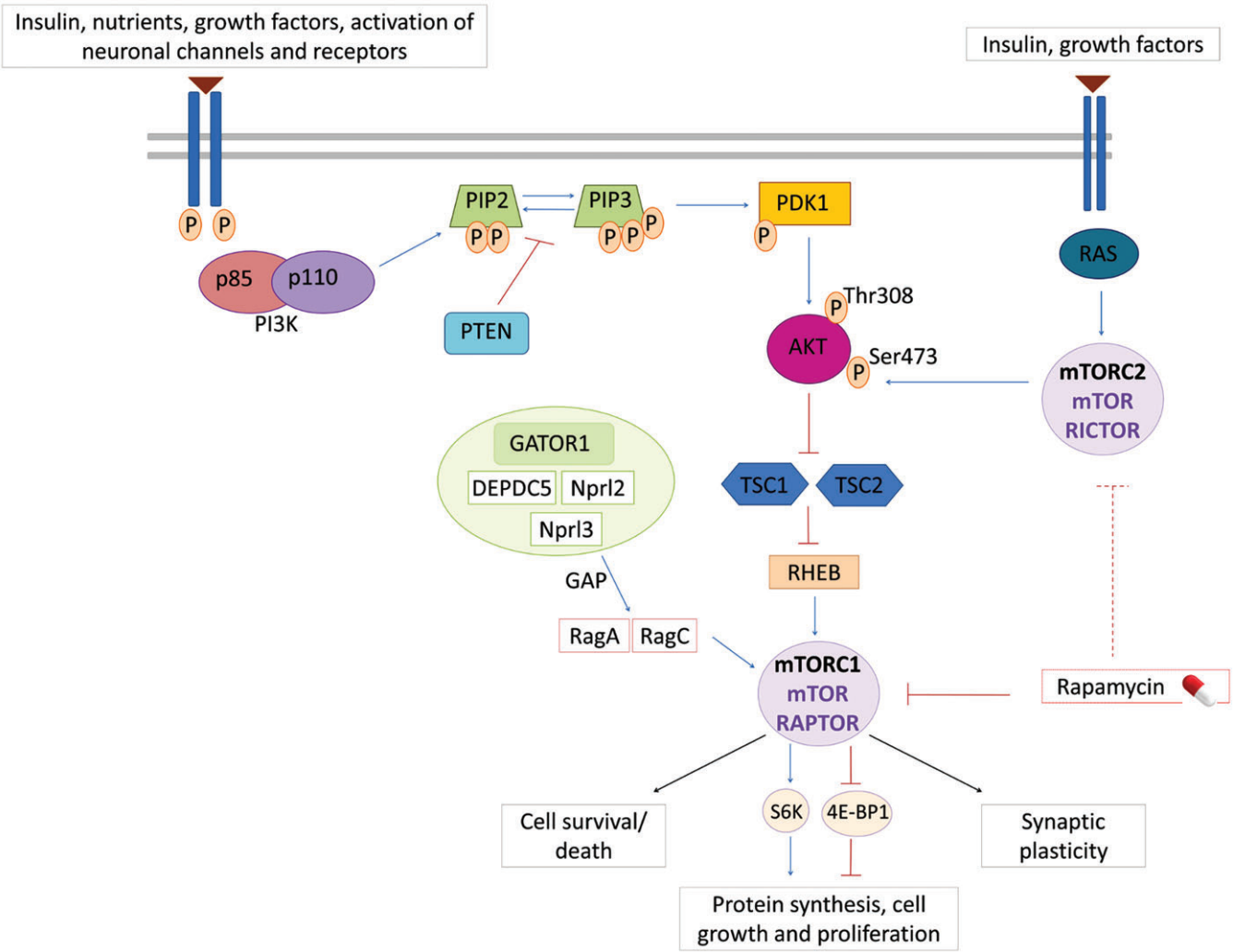

FIGURE 4 The PI3K/PTEN-mTOR pathway regulating cell growth and proliferation. mTOR is activated by signalling through the PI3K-Akt pathway. PTEN, TSC1, and TSC2 act as negative regulators of the mTOR pathway, and removal or loss-of-function mutations lead to hyperactivation of mTOR. mTOR complex 1 (mTORC1) signalling requires activation of the adaptor protein Raptor, and mTOR complex 2 (mTORC2), which is largely insensitive to acute rapamycin treatment, requires activation of the Rictor protein. GATOR1: GAP activity toward Rags (GATOR) complex is composed by Depdc5, Nprl2 and Nprl3. DEPDC5 along with TSC1 and TSC2, acts as a negative regulator of mTORC1. Both TSC1 and TSC2 provide critical regulation of mTORC1 through the GTPase-activating protein (GAP) activity of the TSC protein complex towards the RHEB GTPase. Similarly, the GATOR1 complex provides critical regulation of mTORC1 through its GAP activity on the Rag GTPases. Loss of either of these protein complexes through loss of any one of their critical protein components leads to high-level activation of mTORC1, and downstream effects on anabolic processes, including synthesis of all components needed for organelle synthesis, protein translation, and an increase in cell size

variably present and can include some Noonan-like facial features and an open mouth appearance. Nevertheless, because the 23 patients previously described were ascertained from a series of patients with focal epilepsy, ID, brain anomalies and megalencephaly or hemimegalencephaly, there could be a bias toward neurological phenotypes, giving less importance, or not reporting, other clinical manifestations more frequently described in (germline or somatic) syndromes of the PI3K-AKT-mTOR pathway. Remarkably, 3 of the 4 patients described here were referred with an initial diagnosis of MCAP, showing common features in patients with somatic *PIK3CA* mutations (nevus, skin hyperpigmentation, etc.). Thus, *mTOR* mutations should be considered in those patients with phenotypic overlap with the *PIK3CA* spectrum or other syndromes within this pathway. A list of relatively common findings can be found in Table 1.

The variants in *mTOR* in patients with SKS are distributed all over the gene, and there is great phenotypic variability within patients showing the same mutation, even among those with germline mutations. As with most vascular and/or overgrowth syndromes within the differential diagnosis, all *mTOR* mutations reported in patients with SKS cause GOF in the pathway. However, there are no clear genotype-phenotype correlations. Mutations in the FAT domain are frequent, especially the recurrent variant p.Glu1799Lys, detected in 48.1% of the patients with SKS. It has been functionally showed that some mutations in the FAT domain, especially the variant Cys1483Phe, detected in 3/27 patients with SKS and 2/27 patients with only brain *mTOR* somatic mutations, may decrease the binding of the mTOR endogenous inhibitor Deptor. This suggests that mutations in the FAT protein domain could increase mTOR activity by a decrease in its inhibition; still, it cannot be ruled out

that these mutations, as well as mutations outside the FAT domain, generate an increase of mTOR kinase activity.[30]

Gonadal mosaicism, both of maternal and paternal origin, seems to be highly common in SKS (33.3%), which has implications for genetic counselling. Specifically, a relatively high recurrence risk, compared to de novo mutations, should be considered, although precise recurrence risks cannot currently be provided. A recent hypothesis proposed that the *mTOR* GOF mutation p.Glu1799Lys—present in the 3 families with gonadal mosaicism described then—represents a mutational hotspot in somatic cells (eg, germline and colorectal tissues)[12]. However, these figures may change in the future due to current ascertainment bias.

Germinal mutations, either de novo, inherited from affected parents or due to gonadal mosaicism, were present in 92.6% of the patients with SKS. However, 2 of the 27 patients with SKS have mosaic *mTOR* mutations in all tissues studied, which has important implications for accurate molecular diagnosis (traditional techniques do not detect low mosaicism) and for genetic counselling (ie, recurrence risk and follow-up). It has been suggested that the percentage of mosaicism in somatic mutations could be correlated with the extent of the cerebral malformation,[18] but this is not the case in all patients. Some patients with germinal mutations only present neurological symptoms and some do not show cerebral malformations, in contrast to reported individuals with somatic (Table 3) mutations.[17]

These differences could be explained if germline mutations were less activating than somatic mutations, or by the undetected presence of other affected genes, either with germinal or somatic involvement.[17] Perhaps a combination of these two lies behind the lack of correlation between genotype and phenotype. Different *mTOR* mutations could have different effects on the pathway, especially if it is already differentially modulated by other variant/s in other gene/s. In addition, clarifying these aspects could be of great importance for the use of mTOR inhibitors such as rapamycin, as it efficiently inhibits mTORC1 but not mTORC2, two complexes with different downstream functions (Figure 4). A recent study in renal cell carcinomas reported that although mutations in the FAT domain of *mTOR* led to an increase in both mTORC1 and mTORC2 activities, several of these mutations showed residual mTOR kinase activity after treatment with rapamycin at clinically relevant doses.[31] More studies on the effects of different *mTOR* mutations, as well as on other types of small molecules able to modulate the PI3K/AKT/mTOR pathway, are needed.

Diagnosis in SKS is suspected on the clinical findings and is molecularly confirmed with the detection of germline or constitutive mosaic mutations in *mTOR*. Due to the wide differential diagnosis, as well as to the possibility of mosaicism—with variable alternative allele fractions depending on the studied tissue—we recommend an approach based on the use of deep coverage NGS, testing all genes in the differential diagnosis. Consistent with the gain of function mutations observed in SKS, microdeletions of the gene have not been reported. No biochemical or serologic pathognomonic markers have been documented in patients with SKS. Management in SKS includes treatment of epilepsy and multidisciplinary support. Possible future treatments with rapamycin, or other mTOR inhibitors, may be promising for the prevention of neurocognitive manifestations, including epilepsy, but still needs to be tested.[32]

In conclusion, SKS, caused by germline or mosaic mutations in the *mTOR* gene, is a recently described and clinically discernible disorder characterized mainly by ID, macrocephaly/hemi/megalencephaly, and seizures. Facial dysmorphism and other non-neurological manifestations, may also provide diagnostic clues in some individuals. However, there is a high phenotypic overlap with other syndromes associated with the PI3K-AKTmTOR pathway (ie, MCAP). Since the best tool to make a clinical diagnosis is to think about a specific diagnostic possibility, this paper presents for the first time an in-depth review of this rare disease, which may help not only in the improvement of the clinical diagnosis but also in the diagnostic approach. We have also confirmed mosaic *mTOR* mutations present in all studied tissues (including blood) as a cause in SKS, which have consequences in terms of phenotype and diagnosis. Similarly, the review of all available aspects to date may also be of interest for further clinical management, follow-up, and therapeutic approaches (ie, mTOR inhibitors) on this group of patients.

ACKNOWLEDGEMENTS

This research was supported by the project IP-17 from the call "Todos Somos Raros" (Telemaraton TVE promoted by Fundación Isabel Gemio, Federación ASEM, and Federación Española de Enfermedades Raras), and co-financed by ISCIII, FEDER FUNDS FIS PI15/01481.

Conflict of interest

Nothing to declare.

ORCID

J. Tenorio http://orcid.org/0000-0002-5308-2316
M. Palomares-Bralo http://orcid.org/0000-0002-2727-7654
V. Martinez-Glez http://orcid.org/0000-0002-4680-881X
P. Lapunzina http://orcid.org/0000-0002-6324-4825

REFERENCES

1. Smith LD, Saunders CJ, Dinwiddie DL, et al. Exome sequencing reveals de novo germline mutation of mammalian target of rapamycin (MTOR) in a patient with megalencephaly and intractable seizures. *J Genomes Exomes*. 2013;2:10.
2. Citraro R, Leo A, Constanti A, et al. mTOR pathway inhibition as a new therapeutic strategy in epilepsy and epileptogenesis. *Pharmacol Res*. 2016;107:333–343.
3. Curatolo P, Moavero R. mTOR inhibitors as a new therapeutic option for epilepsy. *Expert Rev Neurother*. 2013;13:627–638.
4. Crino PB. mTOR: a pathogenic signaling pathway in developmental brain malformations. *Trends Mol Med*. 2011;17:734–742.
5. Mirzaa G, Timms AE, Conti V, et al. PIK3CA-associated developmental disorders exhibit distinct classes of mutations with variable expression and tissue distribution. *JCI Insight*. 2016;1(9):e87623.
6. Mirzaa GM, Conway RL, Gripp KW, et al. Megalencephaly-capillary malformation (MCAP) and megalencephaly-polydactyly-polymicrogyria-hydrocephalus (MPPH) syndromes: two closely related disorders of brain overgrowth and abnormal brain and body morphogenesis. *Am J Med Genet A*. 2012;158A:269–291.
7. Keppler-Noreuil KM, Rios JJ, Parker VE, et al. PIK3CA-related overgrowth spectrum (PROS): diagnostic and testing eligibility criteria,

differential diagnosis, and evaluation. *Am J Med Genet A*. 2015;167A:287–295.
8. Eng C. PTEN Hamartoma Tumor Syndrome. 2001 Nov 29 [Updated 2016 Jun 2]. In: Pagon RA, Adam MP, Ardinger HH, et al., editors. *GeneReviews®[Internet]*. Seattle, WA: University of Washington, Seattle; 1993-2017. Available from: https://www.ncbi.nlm.nih.gov/books/NBK1488/.
9. Tenorio J, Mansilla A, Valencia M, et al. A new overgrowth syndrome is due to mutations in RNF125. *Hum Mutat*. 2014;35:1436–1441.
10. Lee JH, Huynh M, Silhavy JL, et al. De novo somatic mutations in components of the PI3K-AKT3-mTOR pathway cause hemimegalencephaly. *Nat Genet*. 2012;44:941–945.
11. Baldassari S, Licchetta L, Tinuper P, et al. GATOR1 complex: the common genetic actor in focal epilepsies. *J Med Genet*. 2016;53:503–510.
12. Moosa S, Bohrer-Rabel H, Altmuller J, et al. Smith-Kingsmore syndrome: a third family with the MTOR mutation c.5395G>A p.(Glu1799Lys) and evidence for paternal gonadal mosaicism. *Am J Med Genet A*. 2017;173:264–267.
13. Parrini E, Conti V, Dobyns WB, et al. Genetic basis of brain malformations. *Mol Syndromol*. 2016;7:220–233.
14. Riviere JB, Mirzaa GM, O'Roak BJ, et al. De novo germline and postzygotic mutations in AKT3, PIK3R2 and PIK3CA cause a spectrum of related megalencephaly syndromes. *Nat Genet*. 2012;44:934–940.
15. Poduri A, Evrony GD, Cai X, et al. Somatic activation of AKT3 causes hemispheric developmental brain malformations. *Neuron*. 2012;74:41–48.
16. Lopez-Gutierrez JC, Lapunzina P. Capillary malformation of the lower lip, lymphatic malformation of the face and neck, asymmetry and partial/generalized overgrowth (CLAPO): report of six cases of a new syndrome/association. *Am J Med Genet A*. 2008;146A:2583–2588.
17. Moller RS, Weckhuysen S, Chipaux M, et al. Germline and somatic mutations in the MTOR gene in focal cortical dysplasia and epilepsy. *Neurol Genet*. 2016;2:e118.
18. Mirzaa GM, Campbell CD, Solovieff N, et al. Association of MTOR mutations with developmental brain disorders, including megalencephaly, focal cortical dysplasia, and pigmentary mosaicism. *JAMA Neurol*. 2016;73:836–845.
19. Mroske C, Rasmussen K, Shinde DN, et al. Germline activating MTOR mutation arising through gonadal mosaicism in two brothers with megalencephaly and neurodevelopmental abnormalities. *BMC Med Genet*. 2015;16:102.
20. Ghahramani NK, Ghahremani S, Lee H, Strom S, Deignan J, Grody W, Nelson S, Vilain E, Martinez-Agosto J. Activating mutations in mTOR cause human overgrowth associated with macrocephaly, intellectual disability, and distinct dysmorphic features. ACMG Annual Clinical Genetics Meeting. Salt Lake City, Utah, 2015.
21. Baynam G, Overkov A, Davis M, et al. A germline MTOR mutation in Aboriginal Australian siblings with intellectual disability, dysmorphism, macrocephaly, and small thoraces. *Am J Med Genet A*. 2015;167:1659–1667.
22. Epi4K Consortium, Epilepsy phenome/genome project, Allen AS, et al. De novo mutations in epileptic encephalopathies. *Nature*. 2013;501:217–221.
23. Lim JS, Lee JH. Brain somatic mutations in MTOR leading to focal cortical dysplasia. *BMB Rep*. 2016;49:71–72.
24. Nakashima M, Saitsu H, Takei N, et al. Somatic mutations in the MTOR gene cause focal cortical dysplasia type IIb. *Ann Neurol*. 2015;78:375–386.
25. Leventer RJ, Scerri T, Marsh AP, et al. Hemispheric cortical dysplasia secondary to a mosaic somatic mutation in MTOR. *Neurology*. 2015;84:2029–2032.
26. Langmead B, Salzberg SL. Fast gapped-read alignment with Bowtie 2. *Nat Methods*. 2012;9:357–359.
27. Pirooznia M, Kramer M, Parla J, et al. Validation and assessment of variant calling pipelines for next-generation sequencing. *Hum Genomics*. 2014;8:14.
28. Li H. A statistical framework for SNP calling, mutation discovery, association mapping and population genetical parameter estimation from sequencing data. *Bioinformatics*. 2011;27:2987–2993.
29. J LHHBDPMSM. bcftools—utilities for variant calling and manipulating VCFs and BCFs. The MIT License. Genome Research Ltd.
30. Grabiner BC, Nardi V, Birsoy K, et al. A diverse array of cancer-associated MTOR mutations are hyperactivating and can predict rapamycin sensitivity. *Cancer Discov*. 2014;4:554–563.
31. Ghosh AP, Marshall CB, Coric T, et al. Point mutations of the mTOR-RHEB pathway in renal cell carcinoma. *Oncotarget*. 2015;6:17895–17910.
32. Clossen BL, Reddy DS. Novel therapeutic approaches for disease-modification of epileptogenesis for curing epilepsy. *Biochim Biophys Acta*. 2017;1863:1519–1538.
33. D'Gama AM, Geng Y, Couto JA, et al. Mammalian target of rapamycin pathway mutations cause hemimegalencephaly and focal cortical dysplasia. *Ann Neurol*. 2015;77:720–725.

How to cite this article: Gordo G, Tenorio J, Arias P, et al. *mTOR* mutations in Smith-Kingsmore syndrome: Four additional patients and a review. *Clin Genet*. 2018;93:762–775. https://doi.org/10.1111/cge.13135